

Synchronous Primary Serous Carcinoma of the Endometrium and Bilateral Ovaries

SHIVALI SEHGAL, SHILPI AGARWAL

ABSTRACT

A 45-year-old, obese and premenopausal female presented with abnormal uterine bleeding. On histopathological examination and immunohistochemistry, synchronous serous carcinoma of the endometrium and bilateral ovaries was diagnosed. There is

paucity of literature on the occurrence of synchronous serous carcinoma of the endometrium and bilateral ovaries. It is important to differentiate independent primary tumours from metastasis because each carries a different prognosis and the clinical management also differs.

Keywords: Serous Carcinoma, Endometrium, Ovaries

CASE REPORT

A 45-year-old, obese and premenopausal female presented with abnormal uterine bleeding. An informed consent was obtained from the patient prior to the investigations. MRI revealed complete replacement of the right ovary by a solid lesion. The left ovary was partially visualized. There was bilateral pleural effusion with ascites along with multiple omental and peritoneal deposits. Clinically, diagnosis of carcinoma of the ovary, Stage IV was made.

We received a specimen of the uterus with cervix measuring 6x4x3 cm with bilateral adnexa. Each tube measured 4 cm in length and each ovary measured 3.5x1.5x1 cm. The endometrium was atrophic. The cut surface of both the ovaries showed grey white homogenous areas which were reaching the capsule. Endometrial thickness was 0.3-0.4 cm. Myometrium appeared unremarkable grossly.

On histopathological examination, the uterus showed tumour in the endometrium which was thrown into papillary fronds and tufts and was seen invading less than half of the myometrial thickness. The papillae were lined by columnar cells with enlarged nuclei with irregular nuclear membranes and prominent nucleoli. Both the ovaries showed tumour tissue with similar morphology which was breaching the capsule. Bilateral fallopian tubes did not show any evidence of dysplasia or carcinoma in the lining, however, tumour deposits were seen on the serosal layer. Sections from the omentum, peritoneum and parametrium also showed tumour. The possibilities included primary endometrial serous carcinoma with involvement of the ovaries, primary ovarian serous carcinoma with involvement of the endometrium and synchronous serous carcinoma of the endometrium and the

ovaries. Origin from the fallopian tube was ruled out due to an unremarkable lining epithelium. Peritoneal origin was unlikely since main bulk of the tumour was in the ovaries and the endometrium. Immunohistochemistry revealed that tumour in the endometrium was ER negative, WT1 negative while that in both the ovaries was ER positive and WT 1 positive [Table/Fig-1-3]. P53 was positive throughout. [Table/Fig-4] illustrates the immunohistochemical features of serous tumours of the female genital tract. Based on these, a final diagnosis of synchronous serous carcinoma of the endometrium and bilateral ovaries was made.

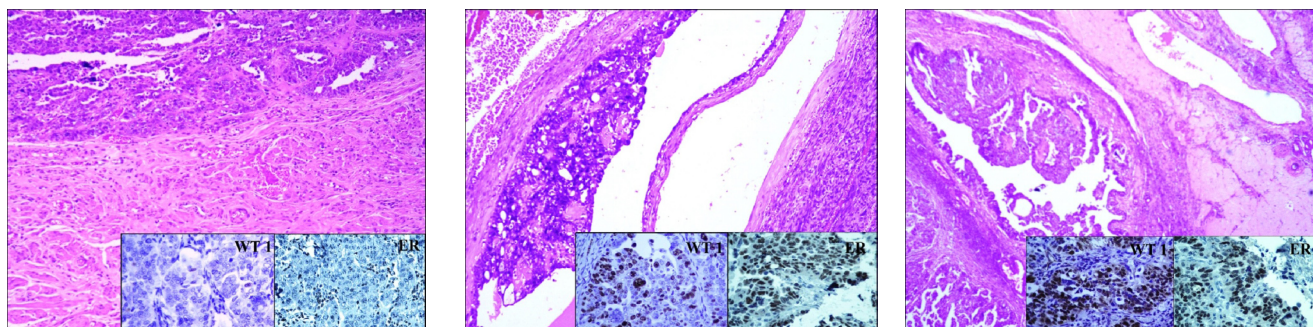
DISCUSSION

Two or more primary tumours which occur closely in time are called synchronous [1]. They may occur at the same site or at different sites and, may have the same or different morphologies. Independent primary tumours of the endometrium and ovary are the most common synchronous tumours of the female genital tract, occurring in 10% of all women with ovarian tumours and 5% of all women with endometrial tumours [2-4].

Various criteria have been described to differentiate between coexisting primary tumours and metastasis. Sometimes, labelling "co-existing ovarian and endometrial cancers" with certainty may be a diagnostic challenge.

The occurrence of synchronous primary cancers of the genital tract is rare, varying from 0.7-1.8% in patients with gynaecologic tumours [5]. Incidence of simultaneous primary tumours of the endometrium and ovary is 0.3% [5].

Eser S et al., evaluated synchronous gynecologic cancers in Turkish women and found that 1% of all gynecological



[Table/Fig-1]: Endomyometrium showing serous papillary carcinoma involving the endometrium which was WT 1 negative and ER negative. **[Table/Fig-2]:** Left ovary showing serous papillary carcinoma which was WT 1 positive and ER positive. **[Table/Fig-3]:** Right ovary showing serous papillary carcinoma which was WT 1 positive and ER positive.

Markers	Ovary	Endometrium	Cervix	Fallopian Tube	Peritoneum	Our Case	
						Ovary	Endometrium
WT1	Strongly +	Negative	+	+	+	Strongly +	Negative
p53	Strongly +	Strongly +	Weakly +	Strongly +	+	Strongly +	Strongly +
ER	Strongly +	Negative	Negative	+	negative	Strongly +	Negative

[Table/Fig-4]: Immunohistochemistry of serous tumours.

tumours were synchronous ovarian and endometrial cancers [6]. Primary tumours of the endometrium, ovary and endometroid adenocarcinoma were the most frequent cancer in synchronous gynecological tumours in Turkish women [6]. Enam et al., reported synchronous endometroid adenocarcinomas in the endometrium and the ovary in a 55 year old multiparous perimenopausal female [7].

Before making a diagnosis of synchronous tumours, it is important to rule out metastasis especially when the tumours at two different sites share the same histomorphology. This requires clinicopathological correlation however, precise criteria are not available, and distinction cannot always be made.

Endometrial carcinoma with metastasis usually has bilateral ovarian metastasis. Metastatic tumours are usually multiple and smaller in size than the primary one. Age of presentation of synchronous tumours is less than that of ovarian and endometrial carcinomas alone [7]. These features are not always helpful and as in the present case, immunohistochemistry may aid in the diagnosis. However, many a times, immunohistochemistry is not conclusive. In these instances, genetic studies and molecular analysis may help in characterization of the tumours.

The etiology of synchronous tumours is different from that of independent primary tumours of the uterus and ovaries. Usually, synchronous tumours are seen in women who are young, obese, premenopausal and nulliparous [7]. Some authors believe "Field effect" may be responsible for synchronous tumours, the same mullerian origin of the uterine wall, fallopian tube and ovary make these organs behave as a morphological unit [8]. Other authors suggest that these

neoplasms originate in metaplasia occurring in histologically similar epithelium of genital tract and peritoneum [9]. Estrogen may also be an important factor in the development of synchronous tumours [8].

Synchronous primary cancers have a better overall prognosis than single organ tumours with metastasis [8,10].

CONCLUSION

It is important to differentiate independent primary tumours from metastasis since prognosis of both varies and the clinical management also differs.

REFERENCES

- [1] Woodruff JD, Solomon D, Sullivant H. Multifocal disease in the upper genital canal. *Obstet Gynecol.* 1985;65:695-98.
- [2] Zaino R, Whitney C, Brady MF, DeGeest K, Burger RA, Buller RE.. Simultaneously detected endometrial and ovarian carcinoma – a prospective clinicopathologic study of 74 cases: a gynecologic oncology group study. *Gynecol Oncol.* 2001;83(2):355-62.
- [3] Soliman PT, Slomavitz B, Broaddus R. Synchronous primary cancers of the endometrium and ovary: a single institutional review of 84 cases. *Gynecol Oncol.* 2004;94:456-62.
- [4] Lou HM, Lou HK, Wu MJ. Synchronous primary cancer of the endometrium and ovary. *Chin J Oncol.* 2006;28:617-20.
- [5] Eisner RF, Neiberg RK, Berek JS. Synchronous primary neoplasms of the female reproductive tract. *Gynecol Oncol.* 1989;33:335-39.
- [6] Eser S, Gulhan I, Ozdemir R, Dicle N, Hanhan M, Baloglu A, et al. Synchronous primary cancers of the female genital tract in Turkish women. *Asian Pacific Journal of Cancer Prevention.* 2011;12:857-59.
- [7] Enam S, Sayeeda N, Choudhury T, Hafiz F. Synchronous ovarian and endometrial carcinoma or metastasis. *Bangladesh J Pathol.* 2011;26(1):32-35.

- [8] Eifel P, Hendrickson M, Ross J, Ballon S, Martinez A, Kempson R. Simultaneous presentation of carcinoma involving the ovary and uterine corpus. *Cancer*. 1982;50:163-70.
- [9] Iris MC, Philip PC, Steven W et al. Synchronous ovarian and endometrial malignancies. *Am J Clin Oncol*. 2000;23(5):521-25.
- [10] Zaino R, Unger E, Whitney C. Synchronous carcinomas of the uterine corpus and ovary. *Gynecol Oncol*. 1984;19:329-35.

AUTHOR(S):

1. Dr. Shivali Sehgal
2. Dr. Shilpi Agarwal

PARTICULARS OF CONTRIBUTORS:

1. Senior Resident, Department of Pathology, Lady Hardinge Medical College, New Delhi, India.
2. Professor, Department of Pathology, Lady Hardinge Medical College, New Delhi, India.

NAME, ADDRESS, E-MAIL ID OF THE CORRESPONDING AUTHOR:

Dr. Shivali Sehgal
Senior Resident, Department of Pathology, Lady Hardinge Medical College, New Delhi-110001 India.
E-mail: shivalisehgal@gmail.com

FINANCIAL OR OTHER COMPETING INTERESTS:
None.

Date of Publishing: Jul 01, 2017