

Xanthomatosis: An Insight to Familial Hypercholesterolemia

JAYA MANCHANDA, RITU GOGIA, SANJAY GOGIA, A.K.VERMA

ABSTRACT

Familial hypercholesterolemia is a "RECEPTOR DISEASE" that is the consequence of a mutation in the gene encoding the receptor for low-density lipoprotein, which is involved in the transport and metabolism of cholesterol. It is associated with skin and tendon xanthomas, xanthelasma, premature arcus corneae and increased risk of premature coronary heart disease.

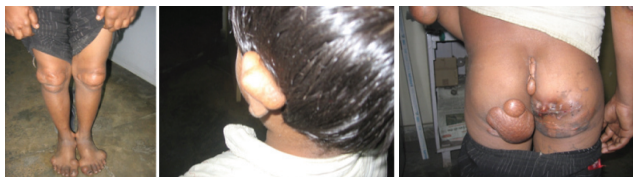Here the author present a case of 10 years old boy who presented with xanthomas and an elevated serum low density lipoprotein. His father had similar clinical history. The subject was Fredericks Phenotype II A – with increased LDL cholesterol. This report is to emphasise the need to screen first-degree relatives and extended family members as early intervention and diagnosis will save the affected individual from catastrophic cardiac events.

Keywords: Lipid laden macrophages, Low density lipoprotein, Xanthomas

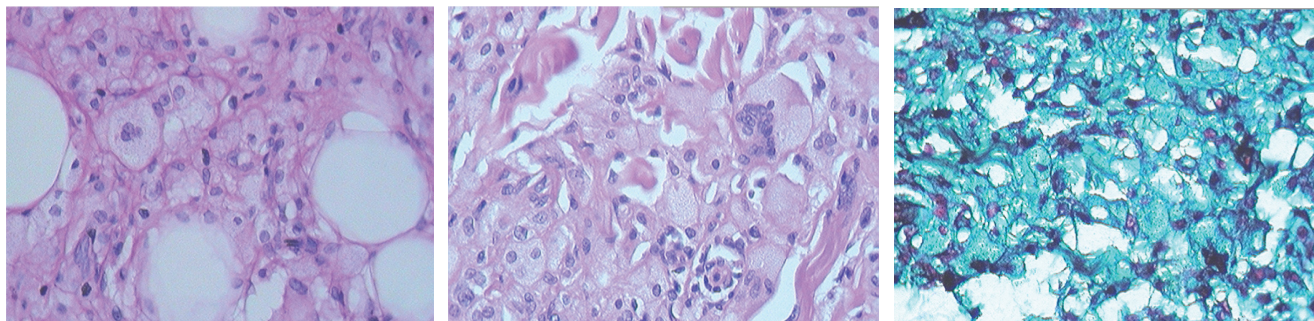
CASE REPORT

A 10 years old boy presented in the Department of Pathology with history of multiple gradually enlarging painless nodules over both elbows, both knees, popliteal fossa, sacrococcygeal area, buttocks, ankles, metacarpophalangeal joints and post auricular regions [Table/Fig-1-3]. His father had similar complaints with nodules over both elbows and altered lipid profile. On the basis of clinical finding it was

thought to be neurofibromatosis, benign mesenchymal lesion or xanthomatosis. There was no history of diabetes mellitus, hypothyroidism, hepatic disease, or renal disease. On physical examination, multiple nodules of varying size were observed on the previously mentioned sites. Systemic examination was unremarkable. Investigations revealed total cholesterol of 713 mg/dl, low density lipoprotein cholesterol of 635.7mg/dl, high density lipoprotein cholesterol of 36.9 mg/dl and triglyceride of 160 mg/dl. Complete hemogram, blood sugar, renal function test, liver function test and thyroid function test were within normal limits. Electrocardiogram (ECG), treadmill tests (TMT) and echocardiography was done to look for the cardiovascular effects of hypercholesterolemia and they proved to be normal. The chest X-ray was normal, while that of hands and elbows showed multiple soft tissue swellings corresponding to cutaneous lesions and



[Table/Fig-1-3]: Xanthomas over the ankle, metacarpophalangeal joints, post-aural and gluteal region.



[Table/Fig-4]: The xanthoma cells have abundant foamy-appearing cytoplasm and small nuclei interspersed in foamy histiocytes (40X) **[Table/Fig-5]:** Touton type of giant cells **[Table/Fig-6]:** Masson's trichrome stain showing collagen bundles interspersed between foamy histiocytes (left to right).

PHENOTYPE	ELEVATED PARTICLES	MAJOR LIPID	FREQUENCY	
I	Chylomicron	TG	Very rare	Eruptive xanthomas common
II A	LDL	LDL	Common	Severe atherosclerosis Tuberous xanthomas Xanthelasmas
II B	LDL and VLDL	LDL, TG	Common	Adult presentation Tuberous xanthomas Xanthelasmas
III	IDL	TC , TG	Rare	Premature atherosclerosis Plane (palmar) xanthomas
IV	VLDL	TG	Common	Eruptive Xanthomas
V	Chylomicron ,VLDL	TG	Uncommon	Acute pancreatitis Plane xanthomas

[Table/Fig-7]: Frederickson classification of dyslipidemia.

normal underlying bones. FNAC performed from one of the nodules yielded scant aspirate and was inconclusive. Biopsy from one of the nodules over the right elbow and buttock showed normal epidermis and aggregates of xanthoma cells separated by fibrocollagenous bundles in the dermis [Table/Fig-4]. A few Touton giant cells were also identified [Table/Fig-5]. On the basis of histopathological findings, diagnosis of benign histiocytic lesion, juvenile xanthomas, tuberous xanthomas, reactive proliferation was thought of. In view of the microscopic picture and clinical features correlation with lipid profile was advised. Masson trichome staining was done for the same [Table/Fig-6]. A final diagnosis of multiple xanthomas –tuberous and tendinous was given.

DISCUSSION

Xanthomas occur due to accumulation of lipid laden macrophages. They develop when systemic lipid metabolism is altered or as a result of local cell dysfunction and may appear as first clinical presentation of familial hyperlipoproteinemia [1]. These patients are at high risk for development of premature coronary atherosclerosis as early stages of disease begin in childhood [2]. If premature development of cardiovascular disease can be anticipated during childhood, the disease might be prevented [3]. Fredrickson classified familial hyperlipidemia into five main types based on the changes in plasma lipoprotein spectrum and other associated changes [4].

Increased concentrations of plasma lipoproteins leads to hyperlipidemia. Genetic defects alterations are classified as primary disorders of lipoprotein metabolism.

Alternatively, other contributing factors, such as diabetes mellitus, hypothyroidism, obesity, pancreatitis, nephrotic syndrome, cholestatic liver disease, dysglobulinemia and as an adverse effect of using certain medications (e.g., estrogens, corticosteroids, systemic retinoid agents) lead to altered plasma lipoprotein concentration and are classified as secondary disorders of lipid metabolism [5,6].

Traditionally, hyperlipidemias have been classified in 6 phenotypes [Table/Fig-7] described by Frederickson based on electrophoretic patterns of elevated lipoprotein levels

in patient. Type I was classified as hyperchylomicronemia, type II as hyper-lipoproteinemia, type III as a combination of both hyper and pre-lipoproteinemia, type IV as hyper-pre-lipoproteinemia, and, type V as hyperchylomicronemia in combination with hyper-pre-lipoproteinemia. Moreover, it was proved that different types of hyperlipoproteinemia had different clinical manifestations, responses to therapy and diet, and different genetic aspects [7].

Xanthomatosis is a cutaneous manifestation of lipidosis in which plasma lipoproteins and free fatty acids are qualitatively altered, resulting in morphologic change as lipids accumulate in foam cells in the tissues. Lipoprotein form by the combination of insoluble circulating lipids (cholesterol, cholesterol esters, triglycerides and phospholipids) and proteins and any alteration in the metabolism leads to an increased risk of cardiovascular disease, pancreatitis or xanthomas [8].

Increased uptake of lipids transported through the capillaries or increased lipid synthesis in the dermal macrophages leads to the formation of foam cells which adhere and form xanthomas [9].

Increase in E- selectin positive endothelial cells and decrease in intracellular cell adhesion molecule cells play a vital role in promoting macrophage migration into xanthomatic lesions [10,11].

Our case was Fredericks Phenotype II A – with increased LDL cholesterol. Phenotype II A includes various disorders including Familial hypercholesterolemia, Familial defective Apo B, Autosomal recessive hypercholesterolemia, Autosomal dominant hypercholesterolemia, Sitosterolemia. Distinction of these entities requires molecular diagnosis and LDL receptor studies. From clinical view there is no compelling reason to perform them since the treatment remains the same

CONCLUSION

This report highlights the pre-requisite of early intervention, pre-prophylaxis and diagnosis to prevent the affected individual and extended family members from impending cardiac events.

REFERENCES

- [1] Goldstein JL and Brown NS: Familial Hypercholesterolemia. In Scriver CR, Beaudet AL, Sly WS and Valle D. (eds.). The metabolic basis of inherited disease. New York, McGraw-Hill pp. 1225-1250, 1989.
- [2] Aggoun Y, Bonnet D, Sidi D, et al. Arterial mechanical changes in children with familial hypercholesterolemia. *Arterioscler Thromb Vasc Biol.* 2000;20(9):2070-75.
- [3] Cortner JA, Coates PM, Liacouras CA, Jarvik GP. Familial combined hyperlipidemia in children: clinical expression, metabolic defects, and management. *Curr Probl Pediatr.* 1994;24(9):295-305.
- [4] Mahajan VK, Sharma NL, Sood S. Xanthoma tendinosum and familial hypercholesterolemia. *Indian J Dermatology.* 2003;48(2):116-18.
- [5] Manley RW, Weisgraber KH, Farese RV. Disorders of lipid metabolism. In: Wilson JD, Foster DW, Kronenberg HM, Larsen PR, editors. *Williams textbook of endocrinology*. 9th ed. Philadelphia: W.B. Saunders Co; 1998. p. 1099-153.
- [6] Shreeya et al. Skin—a mirror of metabolic disorders—a case report. *Indian Journal of Medical Case Reports.* 2015; 4 (3) :36-38
- [7] Fredrickson DS, Lees RS. A system for phenotyping hyperlipoproteinemia. *Circulation.* 1965, 31: 321-27.
- [8] Kumar B, Dogra S. Metabolic Disorders. In Valia RG, Valia AR, editors. *IADVL Textbook of dermatology*. 3rd edition. India: Bhalani Publishing House; 2010, p. 1300
- [9] White LE. Xanthomatoses and lipoprotein disorders. In: Wolff K, Goldsmith LA, Katz SI, Gilchrist BA, Palleo AS, Leffell DJ, editors. *Fitzpatrick's Dermatology in general Medicine*. 7th edition, New York: McGraw-Hill; 2008, p. 1272-81
- [10] Weedon D. *Weedon's skin Pathology*, 2nd edition. London: Churchill Livingstone Elsevier; 2010, p. 961-65.
- [11] Pai VV, Shukla P and Bhoje M. Combined planar and eruptive xanthoma in a patient with type IIa hyperlipoproteinemia. *Indian Journal of Dermatology, Venereology and Leprology.* 2014;80: 467-70.

AUTHOR(S):

1. Dr. Jaya Manchanda
2. Dr. Ritu Gogia
3. Dr. Sanjay Gogia
4. Dr. A.K. Verma

PARTICULARS OF CONTRIBUTORS:

1. Senior Consultant, Star Imaging and Path Lab, ESI Hospital, Basaidarapur, New Delhi, India.
2. Senior Consultant, Star Imaging and Path Lab, ESI Hospital, Basaidarapur, New Delhi, India.
3. Senior Consultant, Star Imaging and Path Lab, ESI Hospital, Basaidarapur, New Delhi, India.
4. Senior Consultant, Star Imaging and Path Lab, ESI Hospital, Basaidarapur, New Delhi, India.

NAME, ADDRESS, E-MAIL ID OF THE CORRESPONDING AUTHOR:

Dr. Jaya Manchanda,
D-76 Second Floor, Amar Colony,
Lajpat Nagar-iv, New Delhi-110024, India.
E-mail: Jaya87manchanda@gmail.com

FINANCIAL OR OTHER COMPETING INTERESTS:

None.

Date of Publishing: Jan 05, 2016